



**PATIENT**

Mojito Letourneau

**SPECIES**

Canine

**BREED**

Chihuahua Mix

**SEX**

Male Neutered

**AGE**

10 years

**WEIGHT**

16.9lbs

**INTERPRETED BY**

Maggie Machen Lamy,  
DVM, DACVIM  
(Cardiology)

**IMAGING PERFORMED BY**

Sabrina Russett, DVM

**HOSPITAL NAME**

Court Street  
Veterinary Hospital

**REFERRING VET**

Dr. Russett

**INVOICE**

45740

**DATE**

11/13/25

**PRESENTING CLINICAL SIGNS**

History: Preop exam showed grade 2/6 heart murmur and arrhythmia. Asymptomatic. Sedated with Alfaxalone, Torb + Propofol. Assess prior to anesthesia.

**ECHOCARDIOGRAM FINDINGS**

2D, m-mode, color flow and doppler imaging is available. Diffuse thickening of mitral valve leaflets (anterior>posterior) with mild prolapse into the left atrial lumen. Mitral regurgitation is difficult to visualize; however, a significant leak is suspected. Moderate left atrial dilation. Mildly increased LV diameter with hyperdynamic myocardial function. The tricuspid valve appears mildly thickened, with no obvious tricuspid regurgitation. Normal right atrial and ventricular diameter. The pulmonic and aortic valves are normal in morphology and mobility. Normal pulmonic and aortic outflow velocities. No aortic or pulmonic insufficiency. No pericardial or pleural effusion noted. No cardiac tumors observed.

**CARDIAC CHART**

| CANINE CARDIAC PARAMETERS   | MR VMAX (m/s) | TR VMAX (m/s) | LA/AO (Boon method) | LA/AO (Heart Base; Swe) | FS (%)                          | EF (%)                                   | EPSS (cm)                                |
|---|---------------|---------------|---------------------|-------------------------|---------------------------------|--|--|
| NORMAL PARAMETER  | 4.5-5.5       | <2.7          | 1.3                 | <1.6                    | 28-40                           | 40-100                                   | <0.6                                     |
| PATIENT   | NM            | NA            | NM                  | 1.6                     | 36                              | 70                                       | NM                                       |
| CANINE CARDIAC PARAMETERS   | HR (BPM)      | AV VMAX (m/s) | PV MAX (m/s)        | BODY WEIGHT (kg)        | LA 2D short axis Base view (cm) | LVIDd Avg; 2D and m-mode short axis (cm) | LVIDs Avg; 2D and m-mode short axis (cm) |
| NORMAL PARAMETER  | 50-100        | 0.7-1.7       | 0.7-1.6             | BELOW                   | BELOW                           | BELOW                                    | BELOW                                    |
| PATIENT   | NM            | 1.2           | 0.8                 | 7.7                     | 2.5                             | 3.3                                      | 2.1                                      |
| *Normal chamber parameters expressed as a mean value (SD)   |               |               |                     | 3                       | 1.27 (5.3)                      | 2.46 (2.46)                              | 1.36 (5.5)                               |
| <b>BODY WEIGHT DEPENDENT PARAMETERS</b>   |               |               |                     | 5                       | 1.40 (4.5)                      | 2.74 (5.2)                               | 1.60 (4.7)                               |
| <i>*Note: All measurements based upon multi-modal images and methods. An average value is reported.</i> |               |               |                     | 10                      | 1.50 (3.8)                      | 3.27 (3.5)                               | 2.06 (3.1)                               |
|   |               |               |                     | 15                      | 1.83 (2.0)                      | 3.71 (2.4)                               | 2.43 (2.1)                               |
|   |               |               |                     | 20                      | 2.02 (1.9)                      | 4.14 (2.2)                               | 2.80 (2.0)                               |
| Adapted from June Boon, Veterinary Echocardiography, 1998   |               |               |                     | 25                      | 2.18 (2.4)                      | 4.48 (2.9)                               | 3.10 (2.5)                               |
| Rishniw M and Hollis NE, J Vet Intern Med 2000; 14:429-435  |               |               |                     | 30                      | 2.33 (3.3)                      | 4.83 (3.9)                               | 3.39 (3.4)                               |
| Hansson et al, Vet Rad and Ultrasound 2002  |               |               |                     | 35                      | 2.48 (4.3)                      | 5.17 (5.0)                               | 3.69 (4.5)                               |
| Bonagura et al. Echocardiography: principles of interpretation, Vet Clin North Am 15:1177, 1995         |               |               |                     | 40                      | 2.62 (5.2)                      | 5.48 (6.1)                               | 3.96 (5.4)                               |
|   |               |               |                     | 50                      | 2.88 (7.1)                      | 6.07 (8.3)                               | 4.46 (7.4)                               |

**INTERPRETATION OF THE FINDINGS & FURTHER RECOMMENDATIONS**

Chronic degenerative valve disease causing suspect moderate mitral regurgitation. Moderate left atrial enlargement indicates there is relatively low risk for imminent complication; however, risk for progression to spontaneous congestive heart failure in the future is elevated. No additional issues such as pulmonary hypertension are identified.

An arrhythmia is mentioned, and an ECG is recommended.

Given the risk for progression and results of the EPIC trial, Pimobendan is indicated in this patient as below. Assessment of progression in the future will help predict long term outcome; however, prognosis is guarded at this stage (B2). Fifty percent of stage B2 patients typically develop CHF



## PATIENT

Mojito Letourneau

## SPECIES

Canine

## BREED

Chihuahua Mix

## SEX

Male Neutered

## AGE

10 years

## WEIGHT

16.9lbs

## INTERPRETED BY

Maggie Machen Lamy,  
DVM, DACVIM  
(Cardiology)

## IMAGING PERFORMED BY

Sabrina Russett, DVM

## HOSPITAL NAME

Court Street  
Veterinary Hospital

## REFERRING VET

Dr. Russett

## INVOICE

45740

## DATE

11/13/25

within 2-2.5 years of diagnosis. The median time to development of CHF in B2 cases treated with pimobendan is 3.5 years.

Omega fatty acid supplementation and mild salt restriction may also be of some long-term benefit. Monitor for development of a progressive cough, labored breathing, exercise intolerance or collapse episodes.

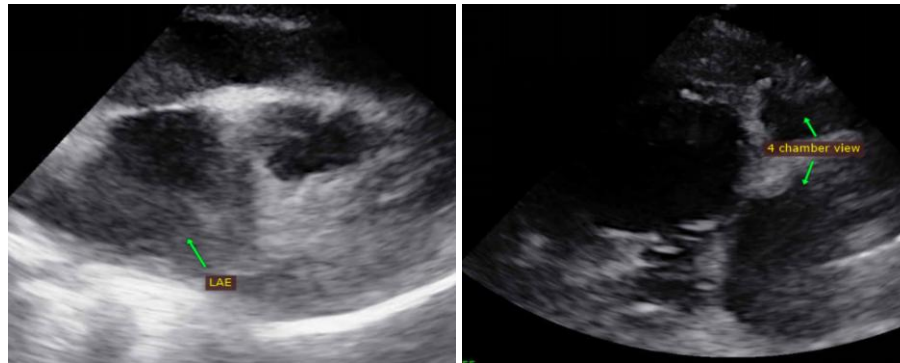
Once on the medication for 3-5 days, anesthetic risk is considered mildly elevated. Cardiac protective drug choices (opioid/benzodiazepine premedication, Propofol or alfaxalone induction, iso or sevo gas) are recommended. Monitor for arrhythmias, hypotension, and hypoxia both intra and post-operatively and intervene as necessary. Judicious IV fluid rates are recommended to avoid fluid overload. Avoid heart rate stimulating drugs such as atropine unless clinically indicated.

## PLAN

Baseline BP and ECG recommended. Institute heart muscle support Pimobendan 0.25-0.3mg/kg PO q12h.

Recommend monitor for progression with a recheck echocardiogram in 6 months, sooner if any development of clinical signs.

## IMAGES



The information and recommendations provided are based on the images presented by the referring veterinarian. No evaluation can be communicated regarding pathology that was not visible in the image/video clips provided.

Thank you for this referral. This report was generated using transcription software, and minor dictation errors may be present. If the clinical or image interpretation does not parallel your findings or if I can be of any further assistance, please contact me.

Maggie Machen Lamy, DVM  
Diplomate of the American College of Veterinary Internal Medicine (Cardiology)  
info@sonopath.com